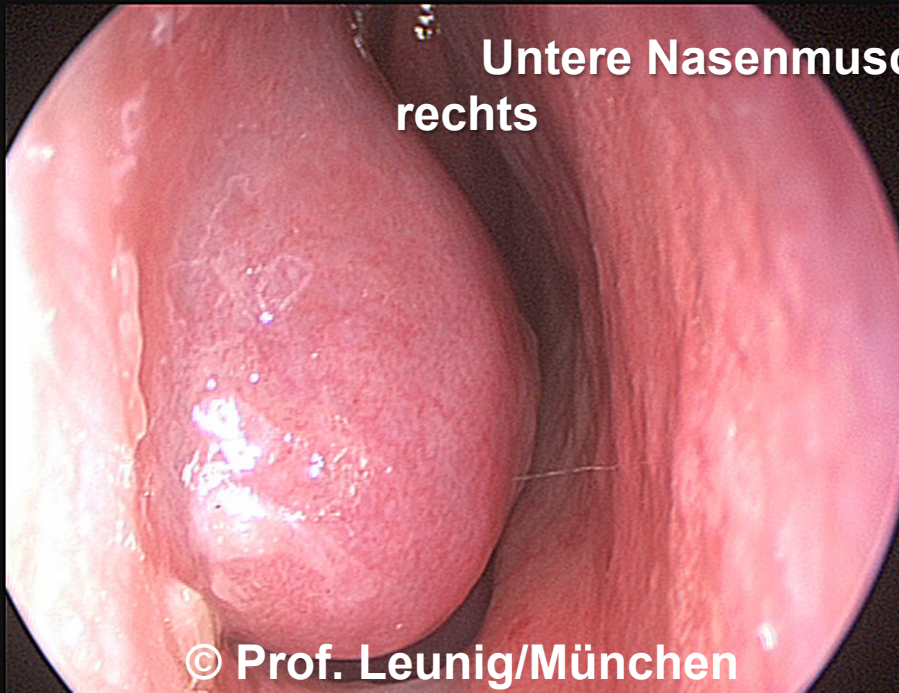
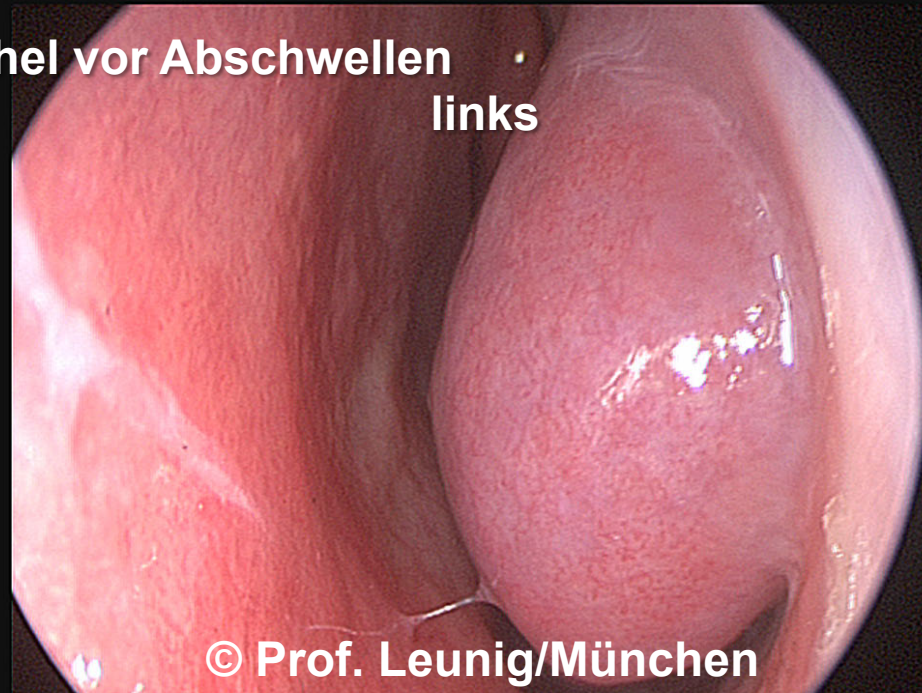

**Untere Nasenmuschel vor Abschwellen**  
rechts



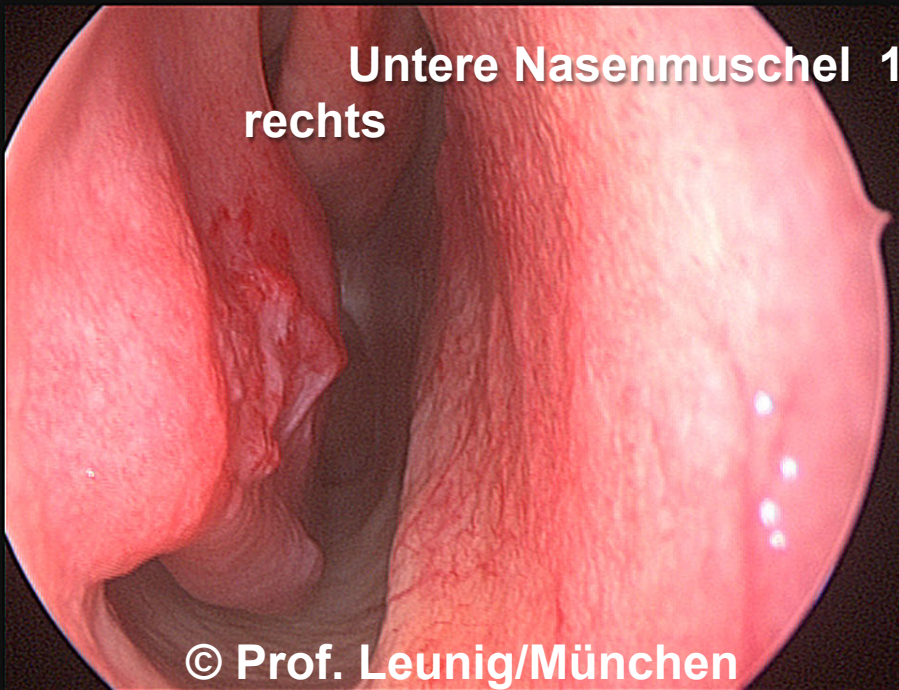
© Prof. Leunig/München

**links**



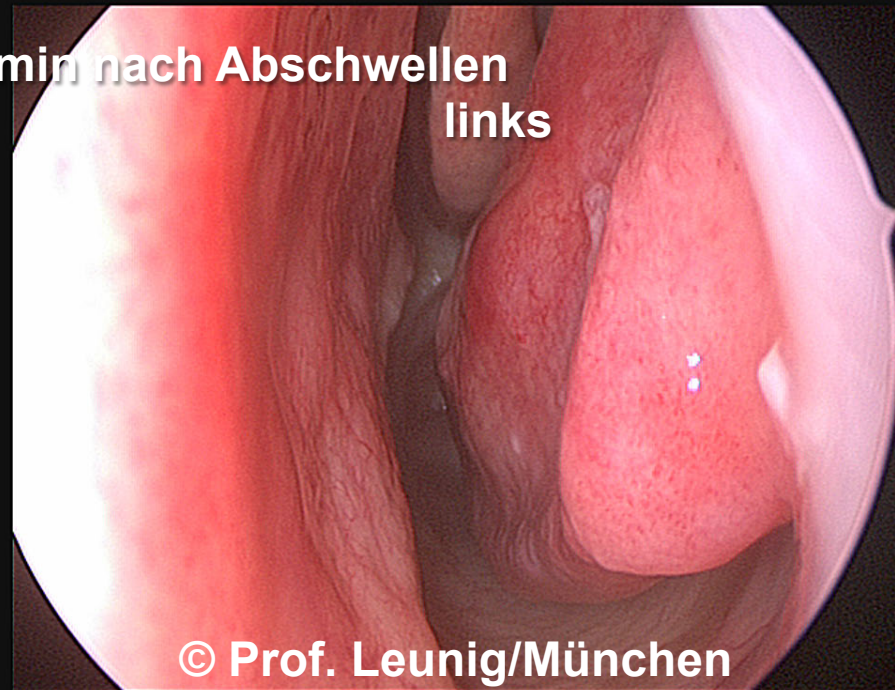
© Prof. Leunig/München

**Untere Nasenmuschel 10 min nach Abschwellen**  
rechts



© Prof. Leunig/München

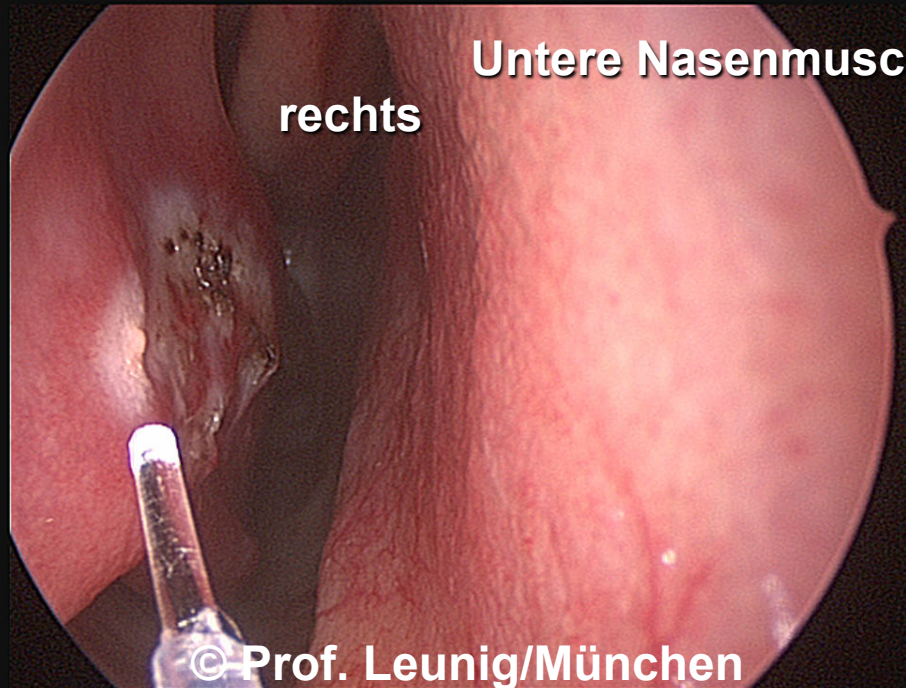
**links**



© Prof. Leunig/München

**Untere Nasenmuschel während Laserkoagulation**

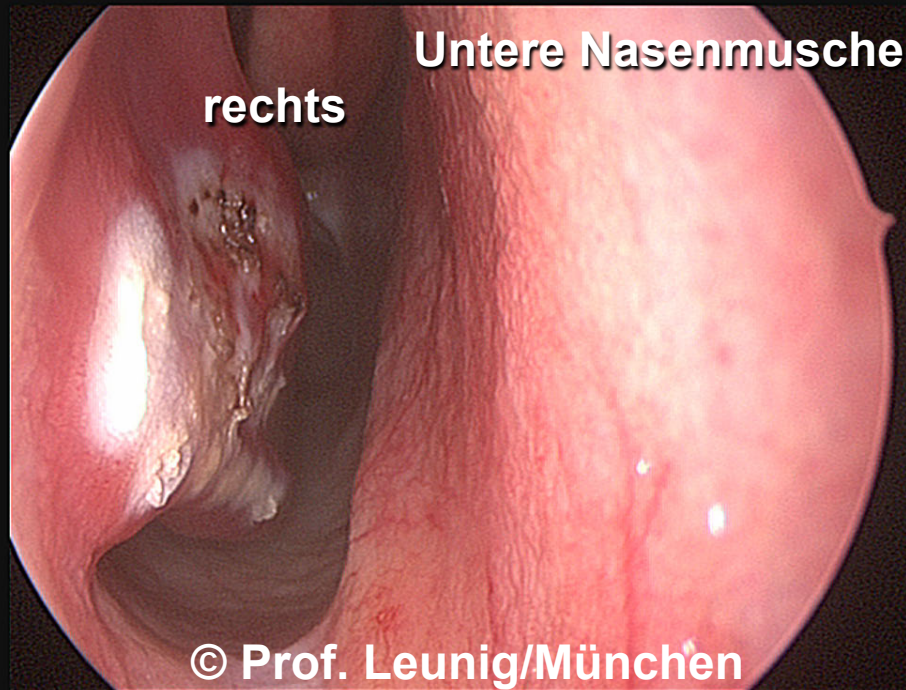
**rechts**



© Prof. Leunig/München

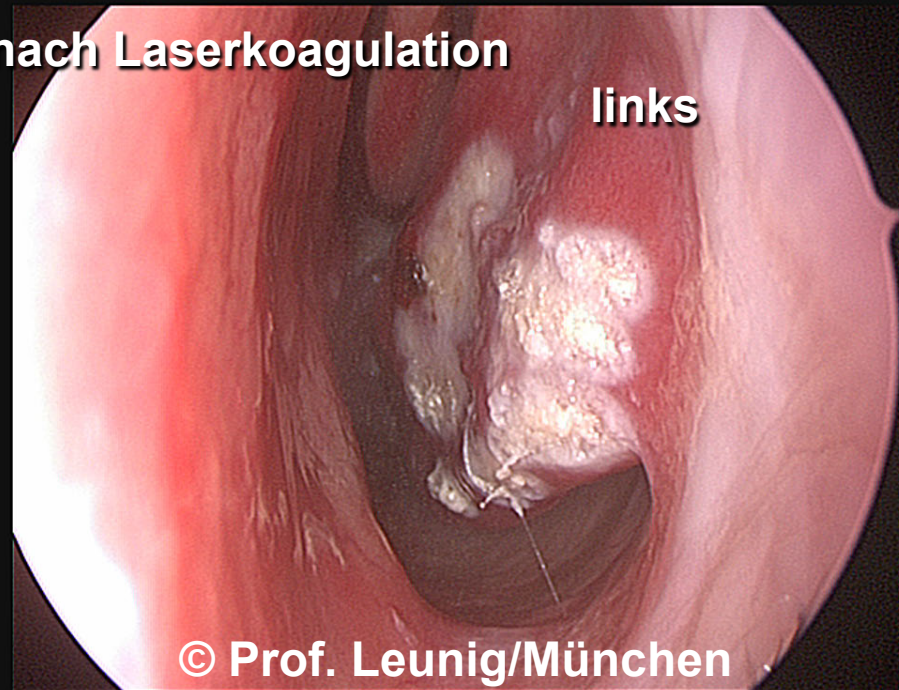
**Untere Nasenmuschel nach Laserkoagulation**

**rechts**



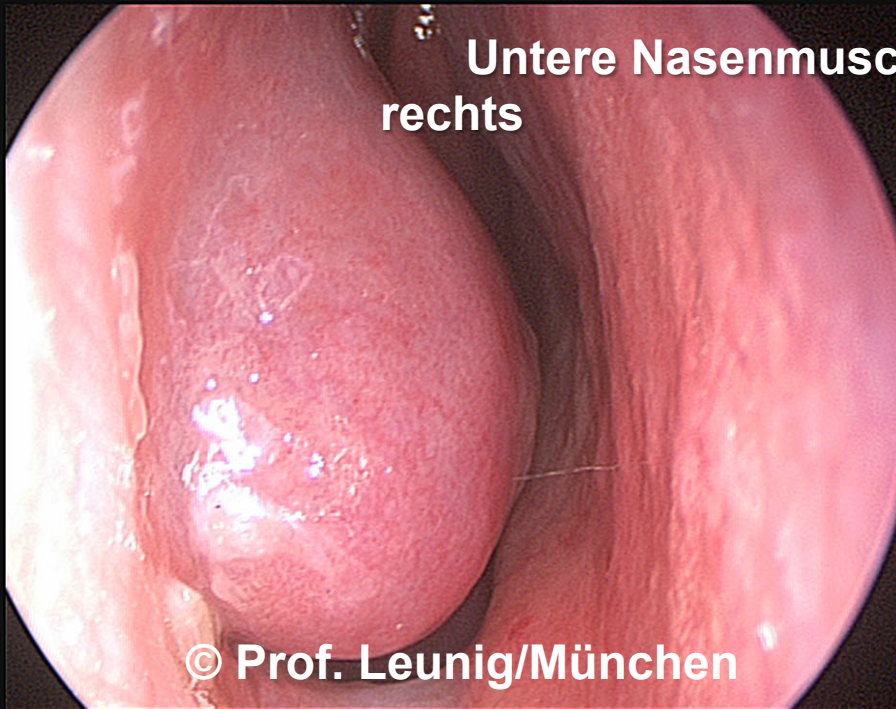
© Prof. Leunig/München

**links**



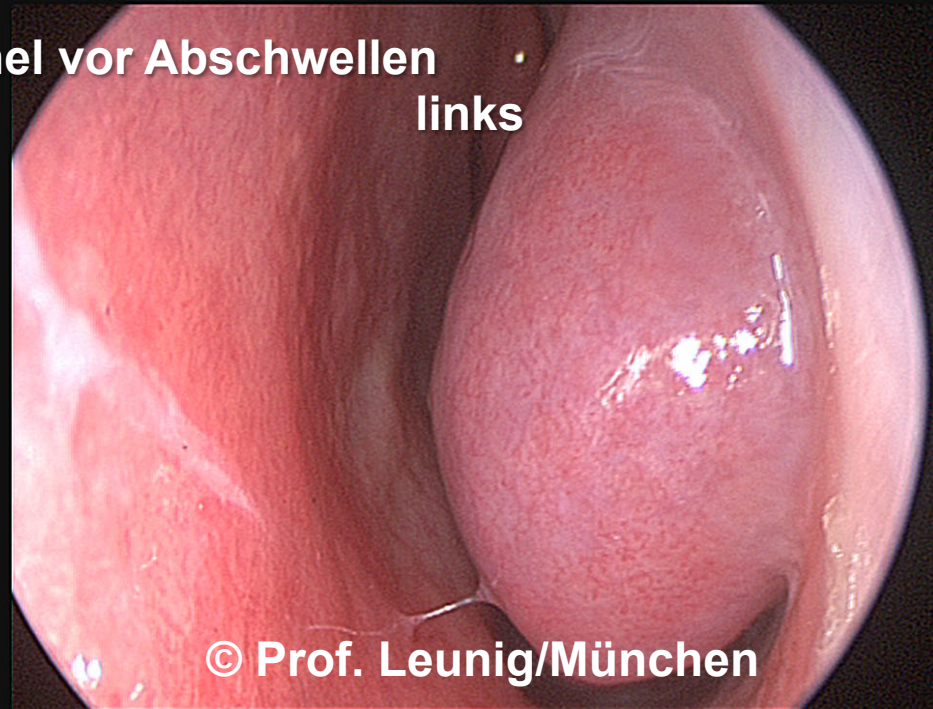
© Prof. Leunig/München

**Untere Nasenmuschel vor Abschwellen**  
rechts



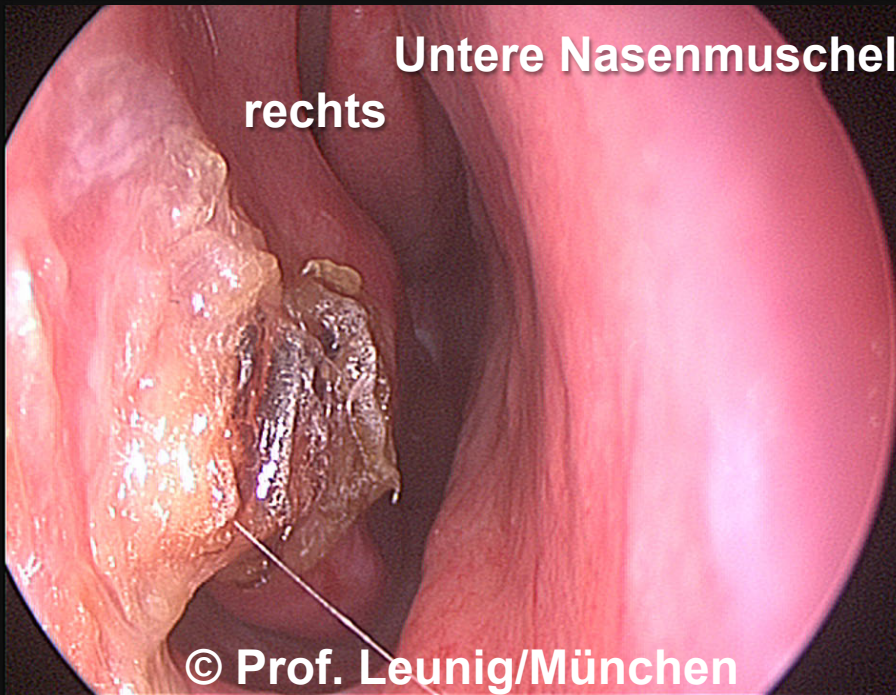
© Prof. Leunig/München

links



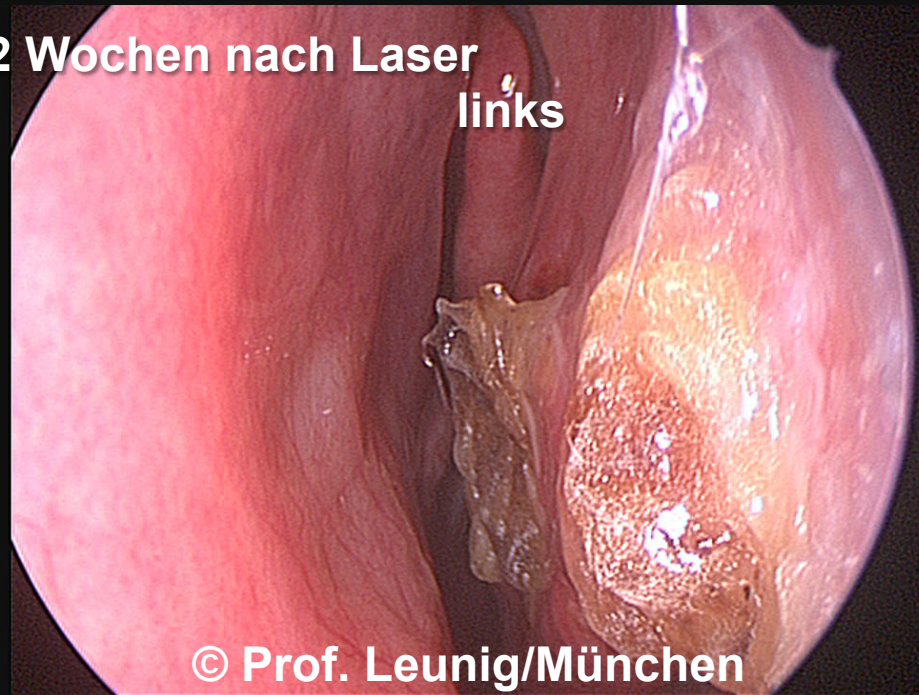
© Prof. Leunig/München

**Untere Nasenmuschel 2 Wochen nach Laser**  
rechts



© Prof. Leunig/München

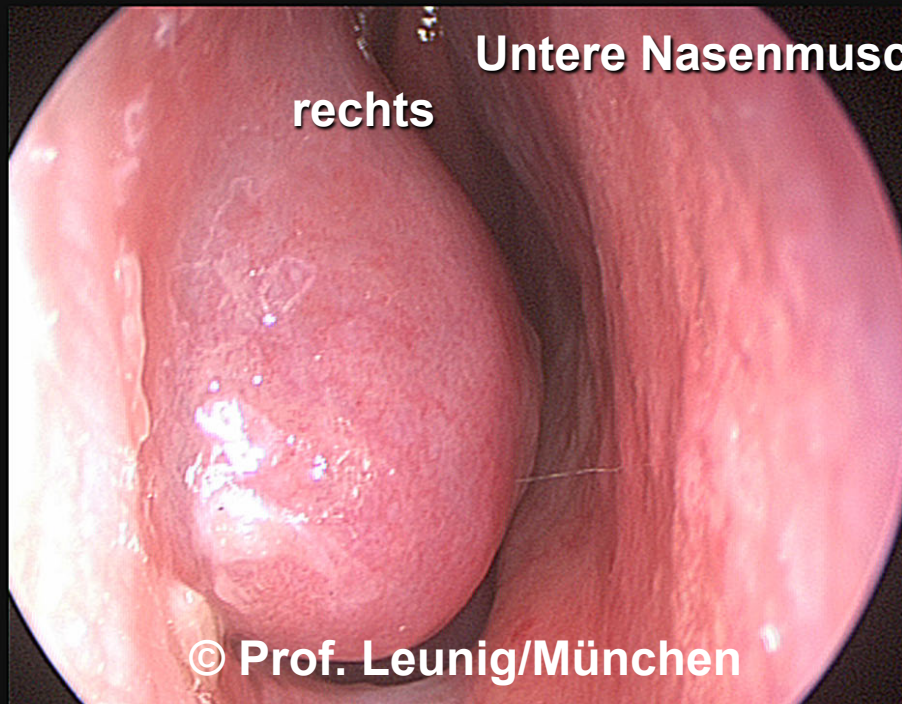
links



© Prof. Leunig/München

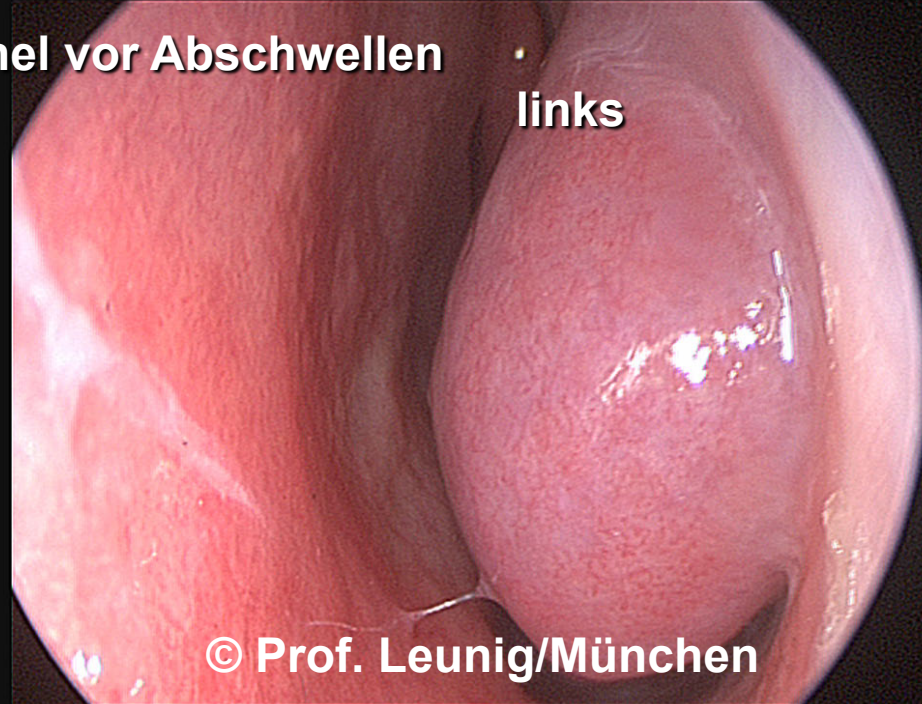**Untere Nasenmuschel vor Abschwellen**

**rechts**



© Prof. Leunig/München

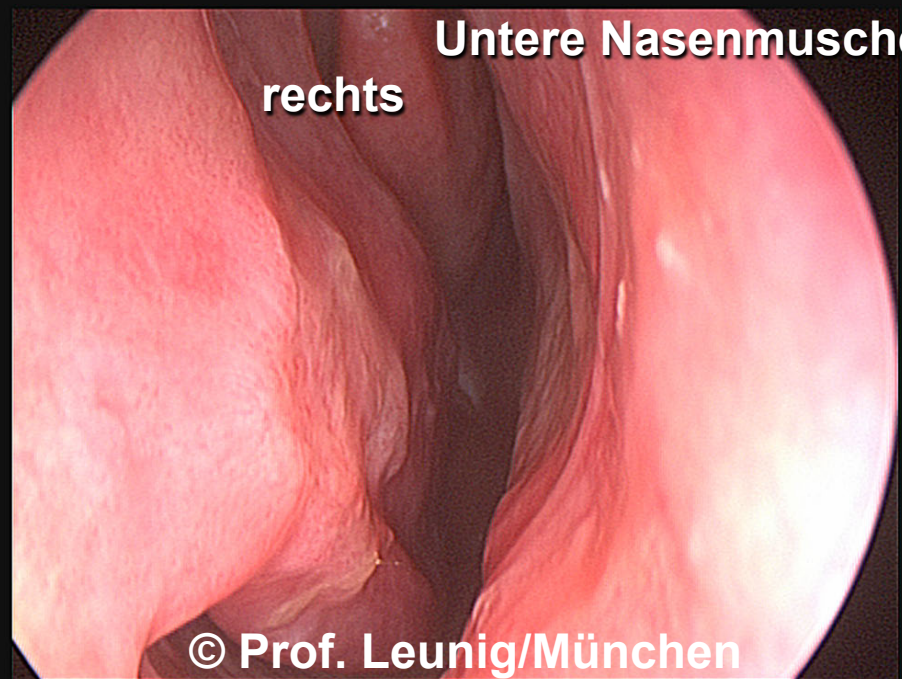
**links**



© Prof. Leunig/München

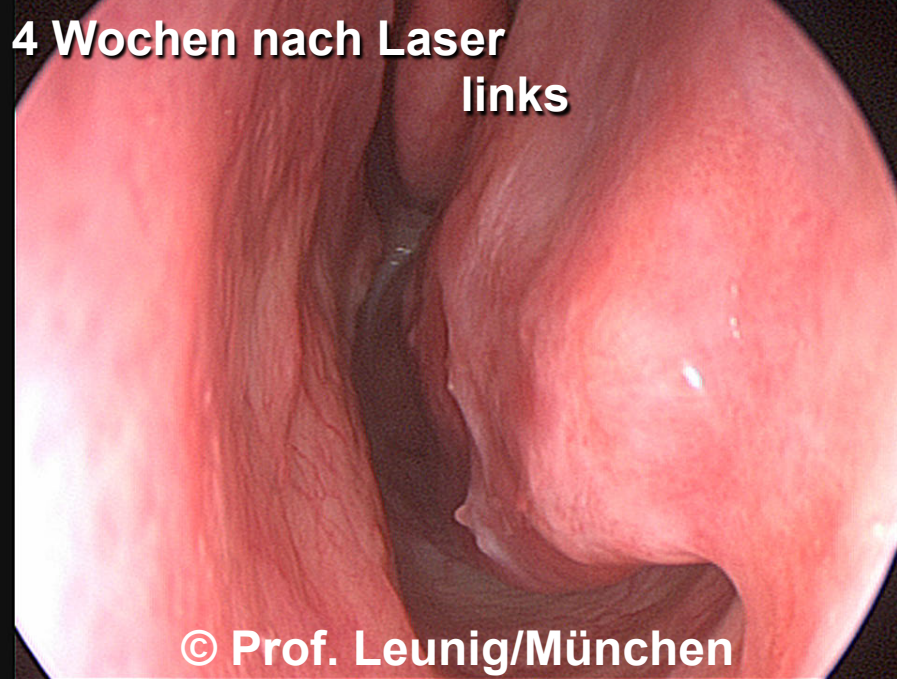**Untere Nasenmuschel 4 Wochen nach Laser**

**rechts**



© Prof. Leunig/München

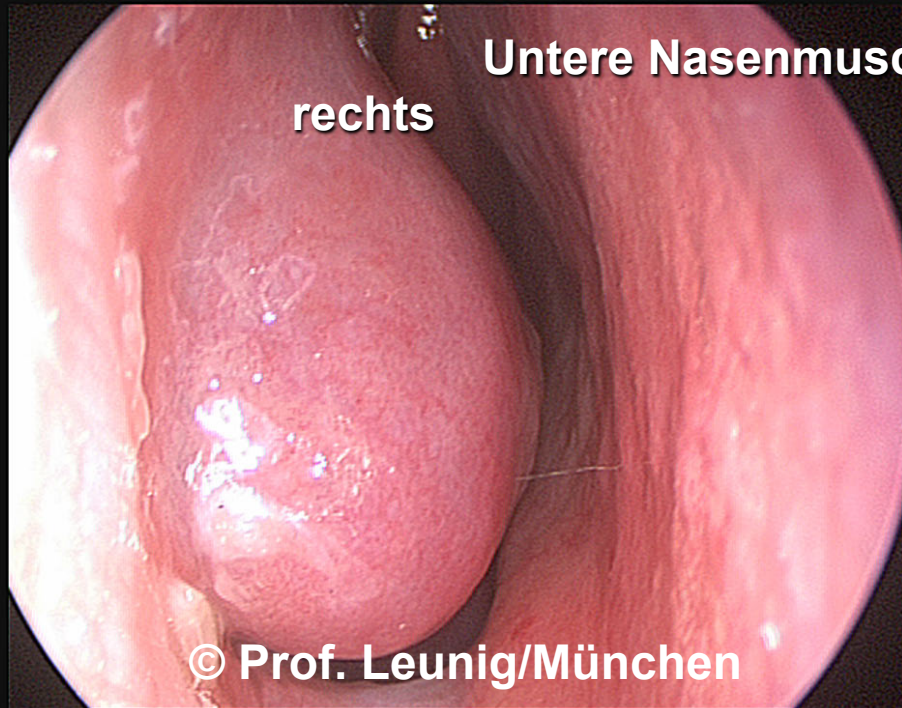
**links**



© Prof. Leunig/München

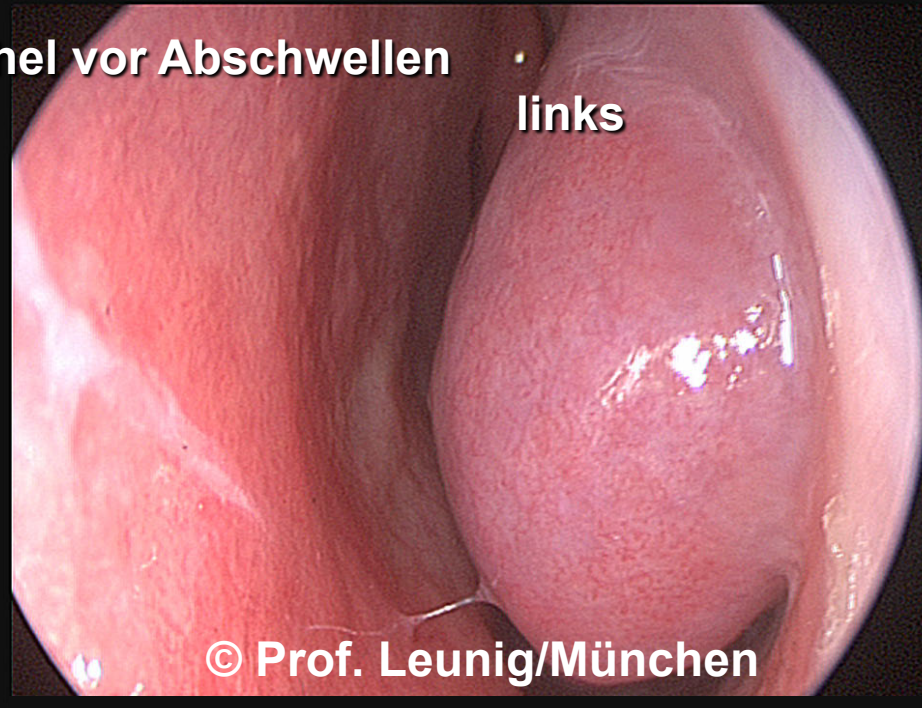**Untere Nasenmuschel vor Abschwellen**

**rechts**



© Prof. Leunig/München

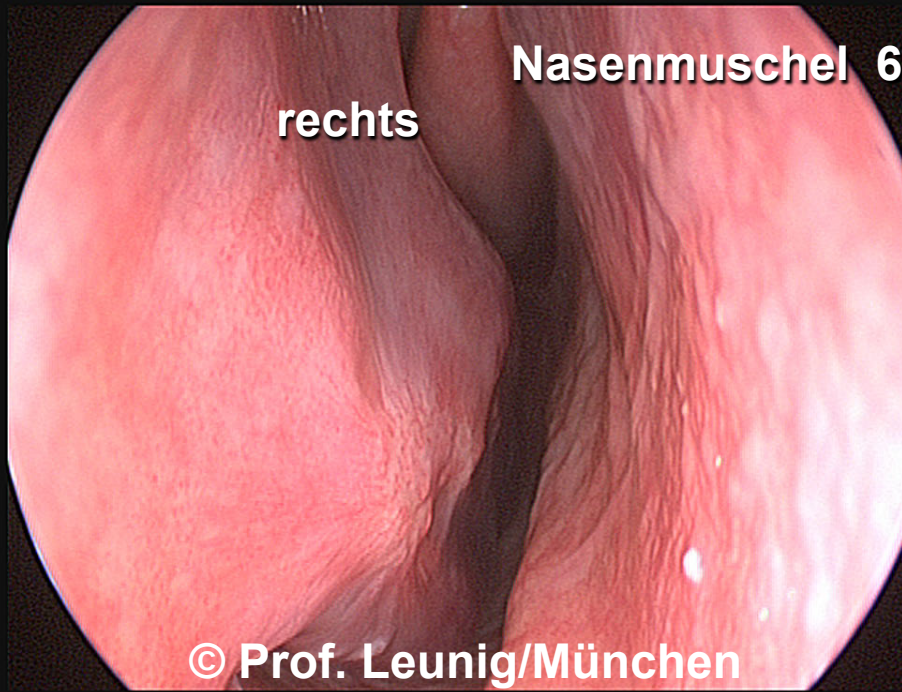
**links**



© Prof. Leunig/München

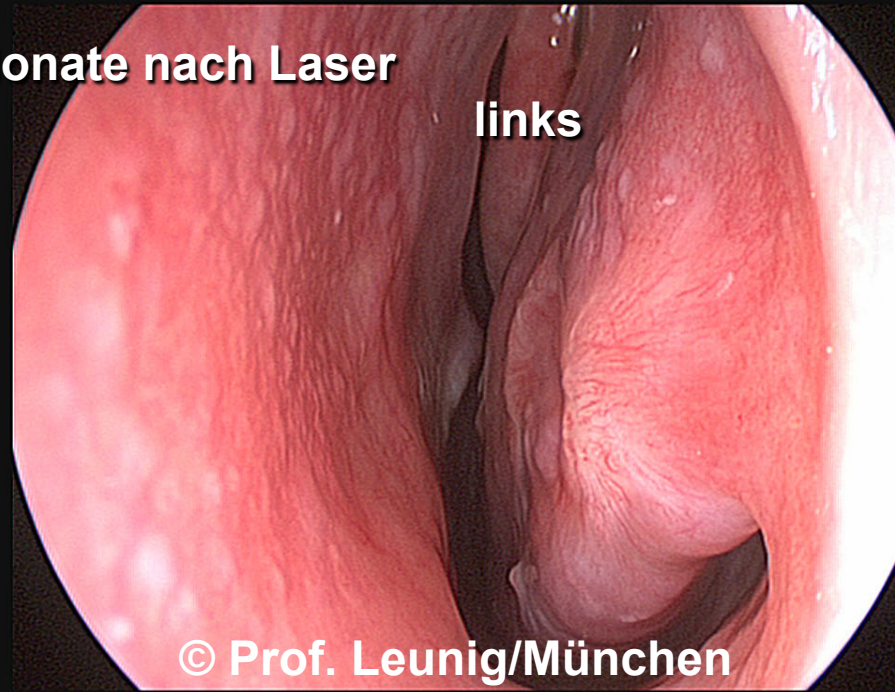**Nasenmuschel 6 Monate nach Laser**

**rechts**



© Prof. Leunig/München

**links**



© Prof. Leunig/München